

SEEING THE DIFFERENCE

Using video laryngoscopes for foreign body airway obstruction

Paramedics from the Montgomery County (Texas) Hospital District (MCHD) are dispatched to a reported cardiac arrest at a local skilled nursing facility. The fire department first responders make initial contact and report the patient is in respiratory arrest.

First responders updated via radio that they suspected probable choking because of observed food particles in the airway as well as the inability to ventilate the patient via bag valve mask (BVM).

On arrival, paramedics place the patient on a three-lead ECG and pulse oximeter. Their initial findings are sinus rhythm at 86 bpm, oxygen saturation of 80% and blood pressure of 132/82.

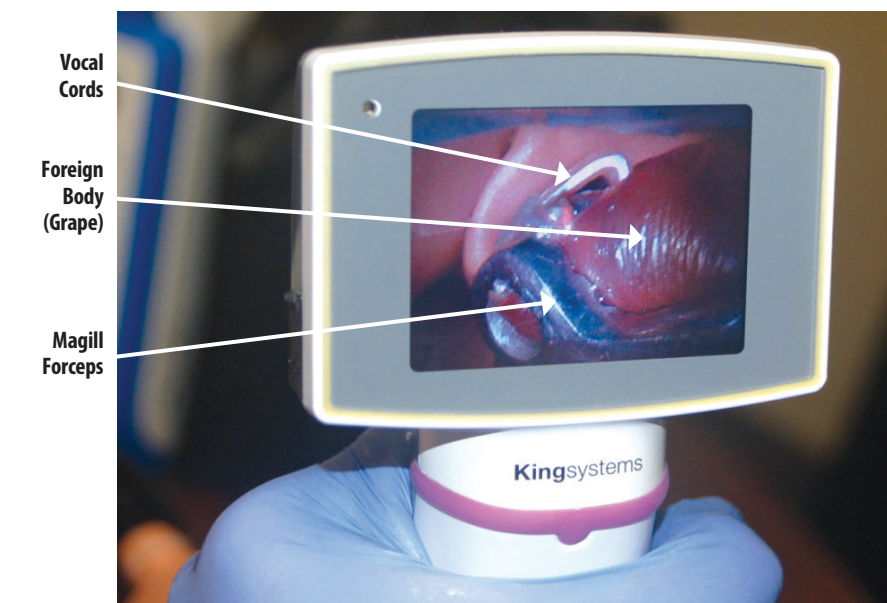
Equipment is gathered and assembled for direct laryngoscopy visualization with the Magill forceps for the removal of the foreign body airway obstruction (FBAO). An end-tidal CO₂ sensor is attached to the BVM and ventilations are attempted by the MCHD crew.

Ventilations continue to be unsuccessful and are halted as direct laryngoscopy is performed. A significant amount of food is seen and removed from the patient's oropharynx. The paramedic performing the procedure no longer sees food in the patient's upper airway.

The laryngoscope blade is removed and the patient's head is repositioned; ventilations are attempted once again without success. Heavy resistance is experienced during BVM attempts, no chest rise is noted and EtCO₂ shows no capnograph or capnometer reading. The patient's oxygen saturation is also shown to be dangerously low.

After the failed attempts to ventilate the patient, the EMS supervisor hands the crew a video laryngoscope. Upon insertion of the device, the paramedic is able to clearly visualize the entire anatomy of the airway, including the epiglottis, vocal cords and glottic opening.

With the enhanced view, the paramedic sees an additional piece of food in the tra-



The video laryngoscope's screen clearly displays a simulated foreign body that remained in the airway after standard removal procedures were attempted. Photos courtesy MCHD

chea, just below the glottic opening. With the video laryngoscope in place, the paramedic uses Magill forceps to remove the remaining food.

The patient almost immediately begins taking agonal gasps. He's subsequently intubated with a 7.5 endotracheal tube (ETT) with continued utilization of the laryngoscope. Successful oxygenation and ventilation (mechanical) are then achieved with multiple confirmation methods and monitors in place, including EtCO₂. The ETT is secured, placement is reconfirmed and transport preparations are made.

During transport, IV sedation is administered per post-intubation protocol, a nasal gastric tube is placed with attached invasive temperature probe, and vital signs are monitored every five minutes.

A positive end expiratory pressure (PEEP) valve is attached to the ventilator circuit and adjusted to 5 cmH₂O. Transport time totals less than 10 minutes with no significant patient changes at the hospital.

On arrival at the ED, the patient is transitioned to a hospital ventilator and cardiac

monitor with ETT placement confirmed by the ED physician and eventual chest X-ray.

The patient is admitted for respiratory failure and released after five days with a discharge diagnosis of pneumonia.

DISCUSSION

FBAO is the fourth most common cause of death due to unintentional injuries in the United States.¹ In 2009, the National Safety Council reported 4,600 fatalities due to foreign body airway obstructions or choking. This emphasizes the importance of emergency airway management as one of the most fundamental aspects of patient care.

Airway management is one of the most essential skills necessary to ensure high quality prehospital patient care. Responders are educated on all types of airway emergencies. However, calls that require advanced airway maneuvers can be extremely stressful and challenging for providers when the unexpected occurs.

As technology evolves, prehospital providers should be able to utilize standard procedures as well as new tools, technology

and methods to mitigate the most austere situations. For example, participants in one video laryngoscopy foreign body study actually preferred Sponge forceps over Magill forceps.²

There are many causes of patient-altered mental status and/or unconscious states. Therefore, it's imperative that rescuers recognize when a FBAO is present and act quickly and efficiently. Responders should attempt to relieve the obstruction, but only if signs of severe obstruction are present or develop.

The signs of severe airway obstruction include the following: cough that becomes silent, respiratory difficulty increases and is accompanied by stridor, and/or the victim becomes unresponsive.³ Early intervention will help achieve favorable outcomes and reduce complications from anoxic brain injury. Pirralo and Milwaukee County EMS Standard of Care—Airway Obstruction algorithm is clear and concise for FBAO.⁴

A retrospective study that included a total of 513 patients showed that 43.5% of FBAOs are resolved prior to EMS arrival. EMS involvement included utilization of BLS on 98 of the patients (19.1%), suction on 12 of the patients (2.3%), Magill forceps on 17 of the patients (3.3%) and 17 patients (3.3%) expired.²

The American Heart Association has stated that the clinical data effectiveness of maneuvers to relieve FBAO are largely retrospective and anecdotal.³ Immediately after evaluation of the physical findings, first responders must be in no doubt of their prehospital emergency care airway basics, including multiple adjuncts and interventions (oxygen, nasal airways, oral airways, endotracheal intubation and surgical airways) for both adults and pediatric patients.

Although fatalities due to FBAO may occur in lesser numbers in adults than pediatric patients, EMS response to airway obstructions in all patients remains a true emergency that must be recognized and managed quickly in the prehospital setting.⁵

MCHD EMS is dispatched to 120 choking calls per calendar year. This case represents cases where standard airway procedures failed to resolve hypoxemia and poor ventilation due to FBAO.

Presently, MCHD and Cypress Creek EMS are conducting a prospective obser-

vational analysis evaluating the intubation skills of the paramedics comparing the use of a video laryngoscopy device versus the standard airway management equipment in an emergent care environment. Institutional Review Board approval and written informed consent was obtained from the paramedics.

MCHD and Cypress Creek EMS participated in comprehensive didactic training and a hands-on troubleshooting session where they learned how to use a video laryngoscope. Each participant was asked to perform an endotracheal intubation (ETI) and was then tested utilizing six Levitan Airway Training Series manikins by means of a randomized schema.

Paramedics then performed ETI on a Laerdal AT Kelly torso manikin with a cervical collar in place. Each participant completed this sequence twice; once using a channeled blade and once using a non-channeled blade with a stylet.

Additionally, each week paramedics continued competency training on both direct and video laryngoscopy on manikins. Their performance was tracked and recorded.

King Vision video laryngoscopes were then placed on each supervisor vehicle and half of the medic units within the two EMS systems. The units assigned the video laryngoscopes are rotated monthly.

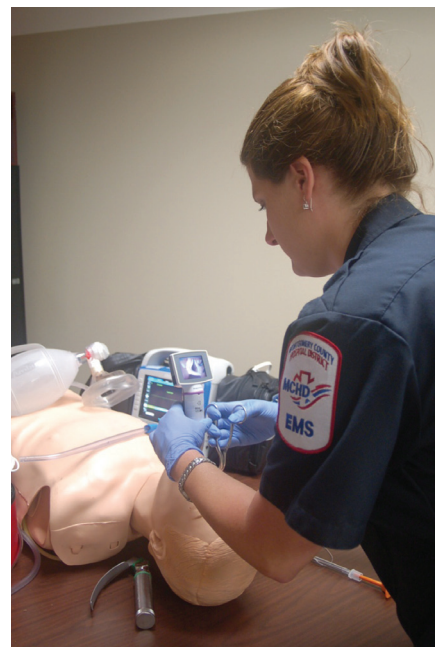First-attempt success rates, primary failures, Cormack-Lehane and Percentage of Glottic Opening scores were measured and recorded.

The paramedic units that responded to the case included in this article didn't have the video laryngoscope assigned during this time period. The primary outcome of this study is the paramedic first-attempt success rate. Summary descriptive/quantitative statistics will be employed for secondary outcomes and study characteristics.

CONCLUSION

This case illustrates that after the exhaustion of typical advanced airway techniques, but prior to surgical airway intervention, the King Vision proved to be an effective tool to facilitate the removal of a potentially life-threatening foreign body airway obstruction.

To assure the successful deployment of video laryngoscopy, EMS systems should ensure and facilitate initial didactic and hands-on training, verification of skills,



An MCHD paramedic demonstrates performing FBAO removal with video laryngoscopy.

continued competency training and tracking of patient outcome metrics. **JEMS**

Kevin A. Mifflin, BBA, LP, **Erik Richenberger**, EMT-P, **Joshua Horning**, NREMT-P, CCEMT-P, EMS-I and **Guy R. Gleisberg**, MBA, BSEE, NREMT-B, EMS-I, work for Montgomery County Hospital District (MCHD) Emergency Medical Services.

Mark E.A. Escott, MD, MPH, FACEP and **Brett J. Monroe**, MD, work for MCHD EMS and Baylor College of Medicine Section of Emergency Medicine.

REFERENCES

1. National Safety Council. (n.d.) Injury facts 2011 edition. Retrieved Oct. 22, 2013, from www.nsc.org/Documents/Injury_Facts/Injury_Facts_2011_w.pdf.
2. Sang MJ, Min JK, Sung PC, et al. Comparison of GlideScope versus Macintosh laryngoscope for the removal of a hypopharyngeal foreign body: A randomized cross-over cadaver study. *Resuscitation*. 2012;83(10):1277–1280.
3. Berg RA, Hemphill R, Abella BS, et al. Part 5: Adult basic life support: 2010 American Heart Association guidelines for cardiopulmonary resuscitation and emergency cardiovascular care. *Circulation*. 2010;122(18 Suppl 3):S685–S705.
4. Milwaukee County EMS. (n.d.) EMS standards of care. Retrieved Oct. 22, 2013, from <http://county.milwaukee.gov/EMS/PoliciesandManuals/EMSStandardsOfCare.htm>.
5. Soroudi A, Shipp HE, Stepanki BM, et al. Adult foreign body airway obstruction in the prehospital setting. *Prehosp Emerg Care*. 2007;11(1):25–29.